



The John Edmeads Memorial Lecture

**Dangerous causes of headache:
how not to miss them!**

R. Allan Purdy, MD, FRCP, FACP

Learning Objectives

- Know the general and specific approaches to dangerous secondary headaches.
- Know by means of cases where the pitfalls to misdiagnose can be found in secondary headaches
- Know what can be done to militate against misdiagnosis of secondary headache.

What is this test show?

GRAPHIC TO BE INSERTED HERE

Case 1 - ER Consult

- 60 with 3 day history of two “blackout” spells, lasting 15m. One prior spell in June 2008.
- After last spell, she was mute. She came to the ER when her muteness failed to resolve.
- The patient is described by the ER physician as having “la belle indifference”.
- She is wearing sunglasses at night in the ER.
- Neuroexam normal except deafness R ear...

Her CT in January 2009

GRAPHIC TO BE INSERTED HERE

The Rest of the story....

- She had a CT head in 2003 for work up of congenital right external ear malformation
- Prior to surgery she had a CT scan as part of the workup!
- The scan follows....

CT Head 2003

GRAPHIC TO BE INSERTED HERE

Past History continued...

- She was admitted for urgent surgery but left AMA.
- Convinced to return for MR & surgery, left MR in the middle of scan & then left hospital AMA to “think things over” .
- FMD referred to neurosurgeon for further counseling- Referral letter noted she said: “I’ve had this for a while, so what’s the rush? Why get so stressed now?”
- Subsequently referred to two more neurosurgeons and AMA declined further MRI studies or surgery after both consultations....



GRAPHIC TO BE INSERTED HERE

August 1, 2003



2003

GRAPHIC TO BE INSERTED HERE

2009

GRAPHIC TO BE INSERTED HERE

One more thing...

- Her 50 year old sister was found dead at home in 1997.
- Autopsy confirmed colloid cyst of the third ventricle with acute massive obstructive hydrocephalus as the cause of death....

Compromise...

- She was admitted to hospital Jan 16th. She was allowed to eat, and given the opportunity to think about surgery in hospital with close neurological monitoring. She refused an MR.
- She underwent endoscopic removal of her colloid cyst on Jan 18th, and is doing well.
- Her speech came back the night before surgery.
- She is still wearing sunglasses, because she has *photophobia*.

Summary

- Colloid cysts of the third ventricle are associated with:
 - Sudden death in otherwise healthy people, most often secondary to acute obstructive hydrocephalus.
- Presenting symptoms:
 - Often vague nonspecific headache, N/V, gait disturbance, disturbed mentation, visual changes are the most common - which makes their timely diagnosis difficult.
- Small, asymptomatic, non obstructing colloid cysts can be safely followed with serial neuroimaging.

References available

Summary Cont'd

- Colloid cysts become neurosurgical urgency/emergency when they increase in size or become associated with hydrocephalus/symptoms of raised ICP.
- Given the possibility for compensated hydrocephalus as evidenced by this case, perhaps small growing lesions with no associated hydrocephalus can also be conservatively managed.
- There is no clear evidence for screening family members of patients with Colloid cysts, though there are a slowly growing number of published case reports of familial Colloid cysts.


References available

What is the 'danger'?

GRAPHIC TO BE INSERTED HERE

Diagnostic Flow

History and Physical



Atypical Features



Secondary Headaches



Investigate

SNOOPing the Atypical!

- **Systemic** symptoms (fever, weight loss) or Secondary risk factors (HIV, systemic cancer)
- **Neurologic** symptoms or abnormal signs (confusion, impaired consciousness)
- **Onset**: sudden, abrupt, or split-second
- **Older**: new onset & progressive headache, in middle-age >50 (giant cell arteritis)
- **Previous** headache history: first headache or different (change in attack frequency, severity, or clinical features)

After AHS Ambassadors Course

Bottom Line for Dx and Rx

- Approach and work-up consists of a *thorough* history taking and a *comprehensive* general and neurological examination
- Formulation of a differential diagnosis biased towards serious etiologies
- Also use appropriate tests and tools to help with diagnosis and management.

Big Ones Needing Accurate Dx...

- Subarachnoid Hemorrhage
- Cerebral Neoplasms
- Low Pressure and High Pressure Headaches
- Meningitis and Encephalitis, Sinus Infections
- Temporal Arteritis
- Vascular: dissection, CVT, hypertension and/or ischemic stroke or intracranial bleed, and subdural or epidural bleed

Big Ones Needing Correct Dx!

- Migraine
- Migraine with Aura
- Cluster Headache
- Probable Migraine
- Variants of Primary Headache
- Chronic and Intractable Headache
- Other....TICs, TACs and TOEs!

Important Points!

- From the patient's point of view **all** headaches are potentially dangerous!
- That is because they worry and obsess about serious disease and sometime have serious secondary disorders or primary disorders...
- OR they develop CDH, Intractable HA, Chronic Cluster, TACs etc...which are very serious disorders making primary variants 'dangerous'!

Diagnosis? Tests?

GRAPHIC TO BE INSERTED HERE

*P*arenchymal, *I*ntraventricular, *T*runcal, *S*ulcal

Life **IS** the PITS!

GRAPHICs TO BE INSERTED HERE

Courtesy of D. Dodick 2008

Read Your Own Tests!

GRAPHICS TO BE INSERTED HERE

2005

2008

The Right Outcome - On the Left!

GRAPHIC TO BE INSERTED HERE



PIN the diagnosis with MR

- Pressure
 - Spontaneous intracranial hypotension
 - Intracranial hypertension
- Infections
 - Meningoencephalitis
 - Cerebritis and brain abscess
- Neoplastic disease
 - Parenchymal and extra
 - axial neoplasms (especially
 - posterior fossa)
 - Meningeal carcinomatosis
 - Metastatic brain tumors
 - Pituitary lesions

**Majority receive
gadolinium**

Recreate the story? What tests?

GRAPHICs TO BE INSERTED HERE



Case of Sudden Headache!

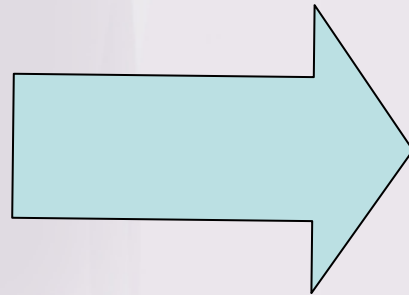
- 54 yr old patient presented with a thunderclap headache..
- Occurred while shoveling snow for a friend - very Canadian thing to do!
- History of migraine and over past three years almost daily headache
- On HRT and had normal exam
- Three visits to the ER before Dx!

Case of Sudden Headache

GRAPHIC TO BE INSERTED HERE

MRA, MRV, CTA, Angiography

- SAH or saccular aneurysm
- AVM or CVT
- Stroke
- RCVS
- Carotid/vertebral dissection
- Vasculitis



Sudden onset headache
±
neurological symptom/sign

Courtesy of D. Dodick 2008

What is diagnosis? Best test?

GRAPHIC TO BE INSERTED HERE



Any thoughts on diagnosis? Tests?

GRAPHIC TO BE INSERTED HERE



Thoughts? Tests

GRAPHIC TO BE INSERTED HERE

Diagnosis? Tests?

GRAPHIC TO BE INSERTED HERE

Diagnostic Considerations? Tests?

GRAPHIC TO BE INSERTED HERE



This test was done! Diagnosis?

GRAPHIC TO BE INSERTED HERE



This test should be done!

GRAPHIC TO BE INSERTED HERE

Diagnosis and Tests?

GRAPHIC TO BE INSERTED HERE

Diagnosis and Tests?

GRAPHIC TO BE INSERTED HERE

What is this test show?

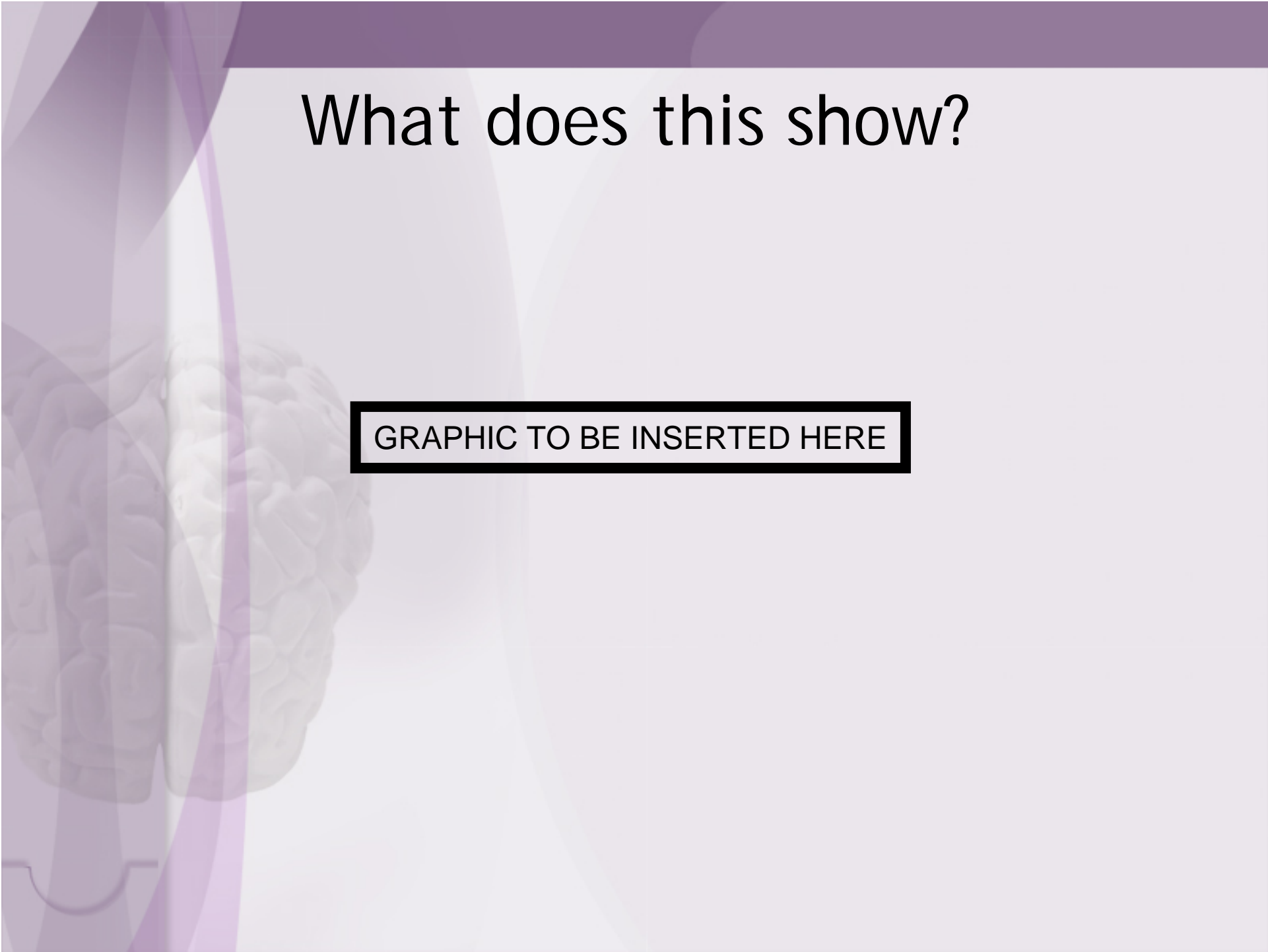
GRAPHIC TO BE INSERTED HERE

What is this?

GRAPHIC TO BE INSERTED HERE

What does this show?

GRAPHIC TO BE INSERTED HERE



Tests - Create Story Clinically?

GRAPHIC TO BE INSERTED HERE

Case of Headache Spells!

- 46 year old woman with migraine for many years, reasonably well controlled on abortive treatment but more frequent and having spells...
- A feeling of not being there, brief and nothing observed by others...
- History of petit mal as child.....

Headache Spells...

GRAPHIC TO BE INSERTED HERE

- Spells occurred every few seconds..
- She was barely unaware of them...
- What would you do with her case?
- She had no myoclonus!
- **She drives a car!!!**

Last Red Flag...

GRAPHIC TO BE INSERTED HERE